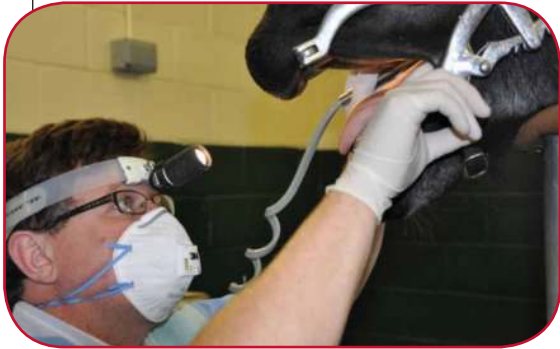
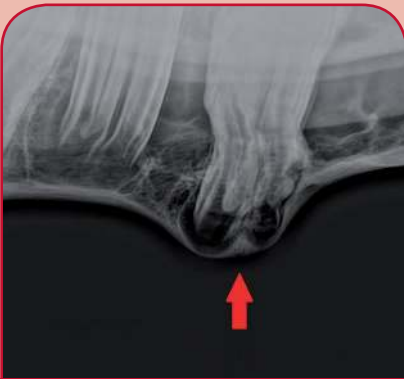
Equine Dentistry - Advanced Dental Care



All horses should receive routine dental care at least once a year to prevent sharp enamel points forming which can cause trauma to the soft tissues of the mouth. As part of this care your veterinary surgeon will carry out a thorough oral examination; this can aid early identification of dental problems that may require further advanced dental care.



**X-RAY OF AN
ERUPTION CYST
ON THE LOWER JAW**

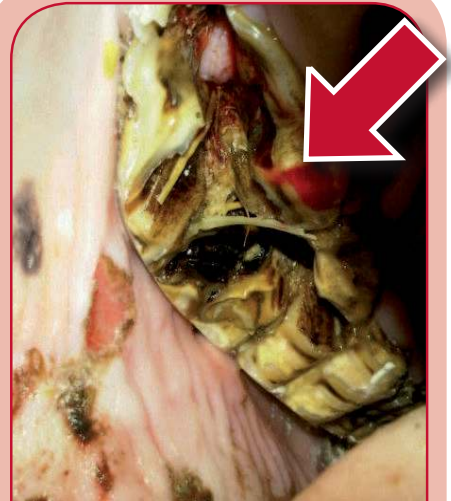
Cheek Tooth Impaction

Caused by excessive compression between the cheek teeth.

Most commonly affects the second and third cheek tooth.

Mild cases develop an eruption cyst – seen as a non-painful lump on the lower or upper jaw at three to four years of age which usually resolve with time.

Severe cases have a large, hot, painful swelling on the jaw that can develop into a tooth root abscess.



**FRACTURED FIRST & SECOND
UPPER CHEEK TEETH**

Tooth Root Abscesses

Most commonly affect younger horses (four to seven years).

There are many causes including trauma, fracture or infection in or around the tooth.

Swelling and a discharging tract are seen if a lower jaw molar is affected. Upper jaw molar root abscesses may have swelling and/or smelly nasal discharge from one nostril.

Diagnosis requires sedation and x-ray to identify which tooth is affected. Sometimes in the early stages there may be little x-ray change and further diagnostic procedures may be necessary.

Treatment requires a long course of antibiotics and, if

appropriate, dental work to correct the underlying problem. Where the sinus is infected flushing is carried out using an in-dwelling catheter. Cases that do not respond to initial treatment will require tooth extraction.

**PERSISTENT
SMELLY
DISCHARGE
FROM ONE
NOSTRIL
CAN BE
SEEN WITH
AN UPPER
TOOTH
ROOT
ABSCESS**



Tooth Fractures

Are caused by trauma, displacements or dental decay.

Diagnosis requires sedation, thorough examination and sometimes x-ray.

Badly fractured teeth may require extraction.

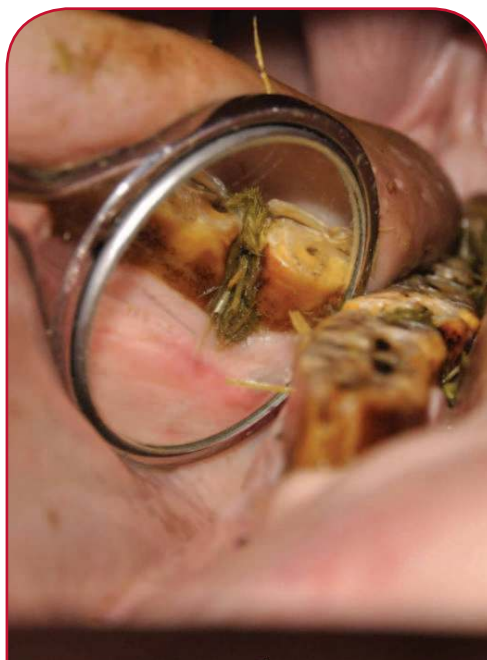Less severe cases are managed by removal of loose fragments, tetanus protection and antibiotic treatment. The opposing tooth is reduced to prevent pressure on the fractured tooth. If necessary the damaged tooth can be stabilised using wire bridges.

A soaked concentrate diet in the short term may be necessary to allow the tooth to rest and heal.

Diastemata and Periodontal disease

A diastema is a gap between the molar teeth into which food packs causing painful gum infection known as periodontal disease. There are many causes including overcrowding, poor tooth compression and displaced teeth.

Signs seen include bad breath (halitosis), quidding (dropping food), weight loss and pouching of food in the cheeks. Affected horses are also more likely to develop choke and impaction colic due to poor chewing of fibre.



A DIASTEMA CONTAINING FOOD MATERIAL

Untreated periodontal disease can lead to complications such as infection of the tooth root, surrounding bones and sinuses.

Diagnosis is made on thorough examination under heavy sedation as these areas are very painful. This involves clearing out all the food material to assess the depth of the gum disease.

Treatment involves flushing out of all the food material. Antibiotic gel and impression material can be used to fill the defect and protect the area from food to allow gum healing. This procedure often needs to be repeated several times.

The diastema may need to be widened using mechanical burs to allow food to move freely out of the space. The procedure requires extreme care to prevent permanent damage to the sensitive structures of the teeth and must only be carried out by a veterinary surgeon.

Occasionally treatment requires tooth extraction in the cases of severely displaced or overcrowded teeth.

A diet of short chopped grass and high fibre nuts can help to reduce the food packing.

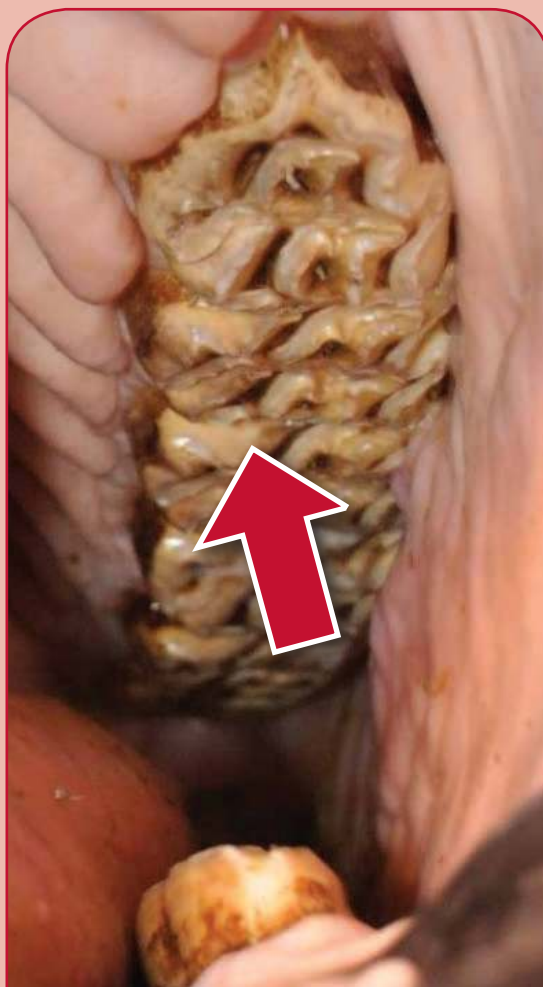Dental Caries

Dental caries is dental decay in the tooth and can weaken the tooth and lead to fractures and tooth root infections.

Caries can only be identified on a detailed oral examination.

Dental fillings can now be performed on these defects to halt the decay process.

The decayed tooth is drilled out, flushed and filled using specialist equipment.



FILLING OF UPPER CHEEK TOOTH

XLequine
Excellence in Practice

XLVets Equine is a novel and exciting initiative conceived from within the veterinary profession made up of independently owned, progressive veterinary practices located throughout the United Kingdom, members of XLVets Equine are committed to working together for the benefit of all their clients.
© XLVet UK Ltd.

No part of this publication may be reproduced without prior permission of the publisher.

For further information contact your local XLVets Equine practice:



Penbode Equine vets - Serving Devon and Cornwall
Holsworthy, Devon, 01409 255 549
Okehampton, Devon, 01837 506 070
www.penbodevets.co.uk